

2017 - IID - MD4043 - eksamen 1
Eksamensdato: 2017-05-16

1

A 25-year-old woman comes to see you, her general practitioner, on an emergency appointment due to a stomach ache which has lasted for two days. She describes a constant pain, initially situated around her navel, now in the right lower quadrant of the abdomen. She has had some loose stools in the last 24 hours, but no urinary symptoms. She is gravida 1, para 0, with one medical induced abortion. She has a stable partner and her periods have been regular, with her last menstrual period four weeks ago.

On examination, she is afebrile and has tenderness on direct palpation and rebound tenderness in the right lower quadrant of the abdomen. Urin dipstick: ery 1+. Urine HCG: negative.

Blood tests: CRP 8 (< 5), leukocytes 11.8 (4.2-8.0).

What is the best way to proceed?

- A** Send her home with an agreement that she can take contact again if necessary, because of suspected menstrual pain
 - B** Refer her to a gynaecological ward for suspected ectopic pregnancy due to her previous abortion
 - C** Refer her to a surgical ward for suspected acute appendicitis
 - D** Refer her to a gynaecological ward for suspected ovarian torsion
-

000015a2a2e51436db

2

You prescribe hormone replacement therapy (HRT) for a patient with menopausal complaints.

What is a common side effect of this treatment?

- A** Accommodation problems
 - B** Weight loss
 - C** Headache
 - D** Recurrent urinary tract infections
-

000015a2a2e51436db

3

What is the gold standard for treating stress incontinence in women?

- A** Botox injections into the bladder
 - B** Tension-free vaginal tape (TVT) surgery
 - C** Anterior colporrhaphy
 - D** Sacral nerve stimulation
-

000015a2a2e51436db

4

A 25-year-old woman comes to see you as her general practitioner due to very frequent urination, urgency. U-stix is negative.

What is the most appropriate first-line treatment?

- A** Bladder training
 - B** Anticholinergic agent
 - C** Electrostimulation
 - D** Tension-free vaginal tape (TVT) surgery
-

000015a2a2e51436db

5

A 55-year-old woman comes to you as her general practitioner for a routine pelvic examination and cervical cytology screening. She has given birth to two children. Her last period was two years ago because she underwent endometrial ablation due to heavy vaginal bleeding. She has no pelvic complaints now.

On examination, the cervix is difficult to locate because of a cystocele that protrudes into the vaginal opening. You finally manage to perform a cervical cytology test.

What is the best treatment to offer her?

- A** Refer her to the hospital for a vaginal pessary fitting
 - B** Refer her to the hospital for an anterior colporrhaphy
 - C** Refer her for electrostimulation
 - D** Local oestrogens and pelvic floor muscle exercise
-

000015a2a2e51436db

6

What definition of heavy menstrual bleeding is most useful in treating women with this condition?

- A Irregular bleeding that results in hemorrhagic anemia
- B Bleeding that reduces the woman's quality of life
- C Bleeding that results in iron deficiency anemia
- D Menstrual bleeding > 80 ml

000015a2a2e5f1436db

7

A 34-year-old woman comes to see you as her general practitioner and tells you she has endometriosis and pain in her left ovary. She underwent diagnostic laparoscopy three years ago with findings of mild endometriosis which was removed during the same procedure. She has since used a hormonal intrauterine device (Mirena) and is amenorrhic. She sometimes has pain when defecating, but a bigger problem is frequent and loose stools 5-10 times a day. She has seen fresh blood in her stools once.

You perform a pelvic examination with normal findings. The uterus is mobile and nontender, and no pelvic masses can be palpated.

As a general practitioner, what is the most correct way to proceed?

- A Refer for a rectoscopy and colonoscopy because of symptoms from the gastrointestinal tract
- B Change her endometriosis treatment from hormonal intrauterine device to contraceptive injection
- C Refer to a gynaecologist because of exacerbation of symptoms relating to endometriosis
- D Recommend mild pain killers such as paracetamol and NSAIDs

000015a2a2e5f1436db

8

A 24-year-old woman comes to see you as her general practitioner. She has a partner whom she lives with and has been trying to conceive for some months. She tested positive on a urine pregnancy test three weeks ago. She tells you she has started to bleed a little.

On examination, you find a small ongoing vaginal bleeding and tenderness in the lower abdomen. What is the most important next step?

- A Refer to a gynaecological ward for examination the next morning
- B Examine s-HCG two days apart
- C Perform a cervical cytology
- D Refer for an abdominal ultrasound the next morning

000015a2a2e5f1436db

9

A 60-year-old healthy woman without symptoms asks whether a routine examination to detect ovarian cancer is indicated.

What is the most correct recommendation you can give her?

- A Serum CA-125 is recommended annually from 45 years of age, followed by a vaginal ultrasound if elevated
- B Routine examination is not recommended because there is no documentation of benefits
- C Serum CA-125 is recommended annually from 45 years of age, followed by a vaginal ultrasound if elevated, in women who have a BRCA 1/2 or HNPCC gene mutation
- D Vaginal ultrasound is recommended annually from 45 years of age

000015a2a2e5f1436db

10

A 70-year-old woman has been examined because of weight loss and increased abdominal girth. Imaging has shown a large ovarian tumour.

What type of ovarian tumour is most likely?

- A Germ cell
- B Epithelial
- C Trophoblast
- D Stromal

000015a2a2e5f1436db

11

Which treatment is most effective in preventing postpartum bleeding?

- A Planned cesarean section
 - B Galaktokinetikum (Syntocinon®) when the child is born
 - C Early clamping of the umbilical cord when the child is born
 - D Oksytocinantagonist (Tractocile®) when the child is born
-

000015a2a2e5f1436db

12

A relatively common and potentially dangerous condition that can occur in any vaginal delivery, but is most common in large fetuses and after surgical delivery, is shoulder dystocia.

What is the most typical finding when examining a woman giving birth with this condition?

- A The head is delivered and the anterior fetal shoulder is stuck on the symphysis pubis
 - B The head is delivered and the posterior fetal shoulder is stuck on the sacral promontory
 - C Twin collision where the shoulders of twin A and B are stuck
 - D The head is delivered and the posterior fetal shoulder is stuck on the spina ischiadica
-

000015a2a2e5f1436db

13

What is placenta accreta?

- A The placenta has grown through the uterine wall
 - B The pregnancy is located in scar tissue from a previous cesarean section
 - C The placenta has attached too deeply in the uterine wall
 - D The placenta has grown through the uterine wall and into neighbouring organs
-

000015a2a2e5f1436db

14

A woman is pregnant in week 32+2. She comes to the pregnancy outpatient clinic because for the past five days she has had a strong skin itch, especially in the palms of her hands and on the bottom of her feet.

What is the most correct way to proceed?

- A Do the following blood tests: biliary acid test, ALAT
 - B Do the following blood tests: allergen-specific IgE
 - C Explain that itching in pregnancy is harmless
 - D Do the following blood tests: platelets, haptoglobin, Hb, ASAT
-

000015a2a2e5f1436db

15

You are a general practitioner. A woman is pregnant for the second time in week 28 and comes to you for a routine examination. She has no symptoms.

The urine dipstick shows: albumin negative, glucose negative, leukocytes 2+, erythrocytes negative, nitrite positive.

What is the most correct way to proceed?

- A You start treatment immediately
 - B You interpret the result as contamination and take no further action
 - C Give her advice on drinking plenty of water and taking Hiprex
 - D You do a urine culture test and wait for the results before you start treatment
-

000015a2a2e5f1436db

16

You are general practitioner for a 32-year-old woman. She is para 0. Her husband has two children from a previous relationship. She has mostly been healthy. She stopped taking birth control pills 6 months ago, when she wanted to become pregnant, and has had three menstrual bleedings since then.

She has a BMI of 27 kg/m². She has been diagnosed with PCOS three years ago by a gynaecologist. What is the most correct information you give her about her upcoming pregnancy?

- A** She has a high probability for becoming pregnant, but she has an increased risk of developing gestational diabetes
- B** If the patient becomes pregnant she must be referred for an early ultrasound and granted sick leave due to increased risk of miscarriage
- C** If the patient becomes pregnant she is referred to the pregnancy outpatient clinic due to an increased risk of pregnancy complications
- D** The patient must probably be referred for in vitro fertilisation in order to become pregnant

000015a2a2e51436ab

17

You are the general practitioner of a 32-year-old woman. She is now pregnant for the third time, in her first trimester. She has previously given birth to two premature children, after spontaneous contractions and rupture of membranes. The first child in pregnancy week 34, the second in week 31.

What is the most correct follow-up during the third pregnancy?

- A** She should follow the general recommendations for routine antenatal care by her general practitioner/midwife
- B** She should be referred to the pregnancy outpatient clinic for assessment by an obstetrician and possibly progesterone treatment
- C** She should be referred to the pregnancy outpatient clinic for assessment for a cervical cerclage (sutures into and around the cervix) and further follow-up
- D** She should be referred for a vaginal ultrasound to measure cervical length in pregnancy week 30

000015a2a2e51436ab

18

You are the general practitioner of a 35-year-old woman. She is pregnant for the second time, and comes to you for her first pregnancy check-up in pregnancy week 10. In her first pregnancy, the child was delivered by cesarean section in week 32 due to serious preeclampsia.

How should the patient best be followed-up during this pregnancy?

- A** The patient should take Albyl-E and be referred to the pregnancy outpatient clinic if her blood pressure starts to rise
- B** The patient should be referred to the pregnancy outpatient clinic in the first trimester for starting Albyl-E, as well as fetometry and Doppler in pregnancy week 24
- C** The patient should take Albyl-E and be referred to an ultrasound for fetometry in pregnancy week 36
- D** The patient should take Albyl-E and be referred to the pregnancy outpatient clinic for further follow-up in the first trimester

000015a2a2e51436ab

19

Progesterone is one of the female sex hormones. The levels of this hormone change during pregnancy.

What is the most correct statement about progesterone and pregnancy?

- A** Progesterone is the hormone analysed in pregnancy tests
- B** A drop in progesterone concentration causes labour to start
- C** Progesterone can be used to induce labour
- D** Progesterone can be used to prevent premature labour

000015a2a2e51436ab

20

Non Invasive Prenatal Test (NIPT) can be used to examine the fetal rhesus D status. In which situation would use of NIPT be the most correct method of testing the fetal rhesus D status?

- A** Testing all rhesus D positive women. If the foetus is rhesus D negative, immunoglobins can be given during pregnancy to prevent the foetus from developing antibodies.
- B** Testing all rhesus D negative women. If the foetus is rhesus D negative, immunoglobins can be given during pregnancy to prevent the mother from developing antibodies.
- C** Testing the rhesus D negative women where rhesus antibodies have been detected in previous pregnancies. Giving immunoglobins during the pregnancy can prevent the foetus from developing anemia.
- D** Testing all rhesus D negative women. If the foetus is rhesus D positive, immunoglobins can be given during pregnancy to prevent the mother from developing antibodies.

000015a2a2e51436ab

21

During the last two months, boy (10) has acquired some strange habits. His shoulders twitch, his eyes blink and he shows signs of unrest to a greater extent than before. Which condition is the most probable?

- A** Tourette's syndrome
- B** Transient tic disorder
- C** Compulsive actions
- D** Chronic tic disorder

000015a2a2e51436ab

22

A 10-year-old boy diagnosed with ADHD comes to see you for a routine appointment about his medication. He has been taking Ritalin (metylfenidat) SR (sustained release) 30 mg daily for the past six months. After talking to him, you conclude that his medication has had a good effect on the main symptoms.

What possible side effects are important to assess?

- A** Reduced appetite, stomach aches or nausea, insomnia, dizziness, head aches, arrhythmias or hypertension, rash, changes in mood and tics.
- B** Increased appetite and weight gain, insomnia, dizziness, head aches, arrhythmias or hypertension, rash, changes in mood and tics.
- C** Reduced appetite, stomach aches or nausea, insomnia, dizziness, head aches, bradycardia or hypotension, rash, changes in mood and tics.
- D** Constipation and stomach aches, insomnia, dizziness, head aches, arrhythmias or hypertension, rash, changes in mood and tics

000015a2a2e51436ab

23

A 16-year-old girl who has previously been healthy comes to see you as her general practitioner. After having had mononucleosis four months ago, she has felt tired. She feels ill after physical exertion, and does not feel well rested after resting. She has not been to school for the past four weeks. She has problems with concentration and memory. When talking to her, you note that she makes good contact and explains herself adequately and coherently. She is in despair and afraid, but has a neutral emotional state. She wants to be able to go to school and meet friends, and can enjoy activities and hobbies like before, but does not feel up for it. If she does join in, she feels worn out for two days afterwards. There are normal findings on clinical examination.

From what you know so far, what is the most probable diagnosis?

- A** Fibromyalgia
- B** Chronic fatigue syndrome or CFS/ME
- C** Depression
- D** Chronic EBV-infection

000015a2a2e51436ab

24

Severe conduct disorder among children and adolescents is difficult to treat. What is the prevalence of this condition?

- A Less than 1 %
 - B About 5-7 %
 - C About 18-20%
 - D About 35-40 %
-

000015a2a2e5f1436ab

25

A 15-year-old girl fled alone from the Syrian civil war and came to Norway one year ago. She has been witness to many bombings. She now experiences strong and very unpleasant physical reactions. Every time she hears the sound of an ambulance she has nausea, palpitations, a fast heart and respiratory rate, numbness in her arms and legs, sweating and intense death anxiety. What is the best explanation for her symptoms?

- A Her symptoms are an expression of inhibited cortical cognitive processes, which can often be seen in traumatised patients. Her current situation in Norway as a refugee, without her parents, creates insecurity and anxiety.
 - B Her symptoms are an expression of suppression of war traumas experienced in the past. The hippocampus plays a central role in the suppression of previous war experiences and maintaining a psychological balance.
 - C Her symptoms are an expression of an alarm response (via the hypothalamus, pituitary gland and adrenal cortex) in a traumatised girl who has been exposed to a non-traumatising, but stress inducing factor (trigger).
 - D Her symptoms are an expression of a stress reaction, mediated through the parasympathetic nervous system. Due to her previous war experiences she can no longer handle loud noises. The ambulance siren is an example.
-

000015a2a2e5f1436ab

26

30 % of girls and 15 % of boys in adolescence (12-20 years of age) experience chronic head ache (monthly or more frequent). For what treatment is there the most evidence for?

- A Paracetamol and relaxation techniques
 - B Cognitive behavioural therapy (CBT) and paracetamol
 - C Relaxation techniques and cognitive behavioural therapy (CBT)
 - D Relaxation techniques and acupuncture
-

000015a2a2e5f1436ab

27

As a general practitioner you meet a mother who is concerned for her child aged 7 months. Recently, she has observed an unusual reaction: Every time she brings her child to a café, the child shows signs of anxiety when strangers are approaching it. Then, the child cries and turns towards her mother. Previously, the child has not reacted in this way. The mother has no knowledge of the child having traumatic experiences with strangers.

What advice do you give and what would you do?

- A This is an unusual reaction in a child this young. The child must be referred for investigation of abuse.
 - B Anxiety in children can persist into adult life, if not treated early. The child should be referred to a child and adolescent psychiatry outpatient clinic (BUP, in Norwegian) for assessment and treatment of anxiety.
 - C You explain to the mother that such reactions are not uncommon in children of this age, and will pass by itself.
 - D The child has a rare anxiety disorder: Early onset social anxiety disorder (EOSAD). Referral to a specialist is necessary.
-

000015a2a2e5f1436ab

28

Some adolescents self-harm by cutting.

What is the most common explanation for why adolescents do this?

- A They self-harm by cutting because they wish to die.
 - B They self-harm by cutting to receive attention.
 - C They self-harm by cutting to cope with an inner restlessness.
 - D They self-harm by cutting because they have auditory hallucinations that instruct them to.
-

000015a2a2e5f1436ab

29

A mother consults the doctor on call with her daughter, 15 years old. The mother found her crying, with a razor and several scratches on her left wrist. She confirmed that she has had suicidal thoughts. She was treated at the child and adolescent psychiatric outpatient clinic (BUP) a year ago for depression and drug overdose with suicidal intention. After six months she was getting better. For the last month, she has felt sad again. Recently, she was drinking heavily at a party and some days ago she had a big quarrel with her best friend.

She sits facing away from you, and does not want to talk to you. She has several visible scars on her forearm and new cuts that are bleeding, but do not need sutures.

You base your assessment on the Health Directorate's national guidelines for preventing suicide, where seven risk factors for suicide are described. How do you assess the risk of suicide in this patient?

- A The risk of suicide is high due to risk factors: psychiatric disorder, self-harm and possible relational loss
 - B The risk of suicide is high due to risk factors: psychiatric disorder, previously attempted suicide and possible relational loss
 - C The risk of suicide is high due to risk factors: psychiatric disorder, self-harm and substance abuse
 - D Her suicidal risk cannot be assessed before speaking to the patient and a description of her suicidal thoughts
-

000015a2a2e5f1436ab

30

A child's attachment pattern to its parents can be said to express the child's internal working model of its parents.

What is such a model?

- A An inner working model is the child's genetic, innate need for being close to and care from its parent
 - B An inner working model are expectations to a parent based on experiences with the other parent.
 - C An inner working model is a memory script based on experiences of limits set by the parent.
 - D An inner working model is a cognitive and emotional representation of the child's experiences of care with its parent.
-

000015a2a2e5f1436ab

31

What is the most likely cause of jaundice in a newborn the first 24 hours after birth?

- A Physiological hyperbilirubinaemia
 - B Hemolysis due to blood group antibodies
 - C Bile duct atresia
 - D Breast milk induced hyperbilirubinaemia
-

000015a2a2e5f1436ab

32

As a doctor at a mother and child health clinic, you examine a child in a six-week check-up. You find a clear murmur from the heart and suspect a heart defect. Later an ultrasound examination reveals that it is a ventricular septal defect (VSD). The parents wonder why this was not detected during the newborn examination at the hospital.

Which of the following explanations is the most likely?

- A** There was no murmur because the ductus arteriosus was still open
 - B** There was no murmur because the heart defect was so small at birth
 - C** The murmur was too difficult to recognise for an inexperienced doctor.
 - D** There was no murmur because of low pulmonary pressure immediately after birth.
 - E** There was no murmur because of high pulmonary pressure immediately after birth
-

000015a2a2e5f1436ab

33

An 8-month old girl has been vomiting for the last 24 hours. In the Admission and Emergency department at the hospital she appears listless and pale. Her weight is now 8 kg, but she weighed 9 kg at the last health centre check up. The doctor on call at the Admission department thinks she appears dehydrated, and wants to start rehydration immediately.

How much fluids should the doctor give intravenously in the first 30-60 minutes?

- A** 40-80 mL
 - B** 90-180 mL
 - C** 240-320 mL
 - D** 360-450 mL
-

000015a2a2e5f1436ab

34

Mari is 1 ½ years old. She is previously healthy, apart from being admitted to hospital 4 weeks ago. The discharge summary describes that rhinovirus was detected, the diagnosis being bronchiolitis, she had airway obstruction and was given inhalations with NaCl (physiological saline).

Mari and her mother come to your GP office. Mari has had a cough since being discharged, initially a productive cough with mucus, but now more of a dry cough. She has been afebrile. She coughs a lot during the night and in cold air. The mother wants help to make the cough better. On auscultation, you can hear scattered wheezing sounds.

What is the best way to handle this patient?

- A** Start asthma medication with inhaled corticosteroids (daily) and beta 2-agonist (when needed)
 - B** Start beta 2-agonist (when needed).
 - C** Perform a nasal swab for several respiratory viruses, to clarify whether she has a new viral infection.
 - D** Start penicillin based on suspected secondary bacterial infection.
-

000015a2a2e5f1436ab

35

Anne, 2 years old, has a reduced general condition, a high fever and elevated CRP. You suspect a urinary tract infection. She has had many UTIs previously, and you think it is very important to get a urine sample of high quality.

How do you perform Anne's urine sample?

- A** Sample from bag put on after washing
 - B** Sample from a urinary catheter
 - C** Ultrasound guided sample from the renal pelvis.
 - D** Sample from urine in the diaper
-

000015a2a2e5f1436ab

36

Per is 7 years old and wets the bed every night. He has no urinary leakage during daytime. What treatment would be most effective?

- A** An anticholinergic agent
 - B** No drink after dinner
 - C** Plenty to drink during daytime
 - D** Antidiuretic hormone
-

000015a2a2e5f1436b

37

Jenny is 15 years old and has had celiac disease for five years, and should be on a gluten-free diet. However, for the last year she has been sloppy with her diet, and blood tests have shown elevated anti-transglutaminase antibodies. You explain to her that she has an increased risk of developing complications from her celiac disease.

What complications does Jenny have an increased risk of?

- A** Pancreatitis
 - B** Lymphoma
 - C** Gastroesophageal reflux disease (GERD)
 - D** Leukemia
-

000015a2a2e5f1436b

38

Cerebral palsy is caused by an injury to the immature brain. When is the most common time of injury?

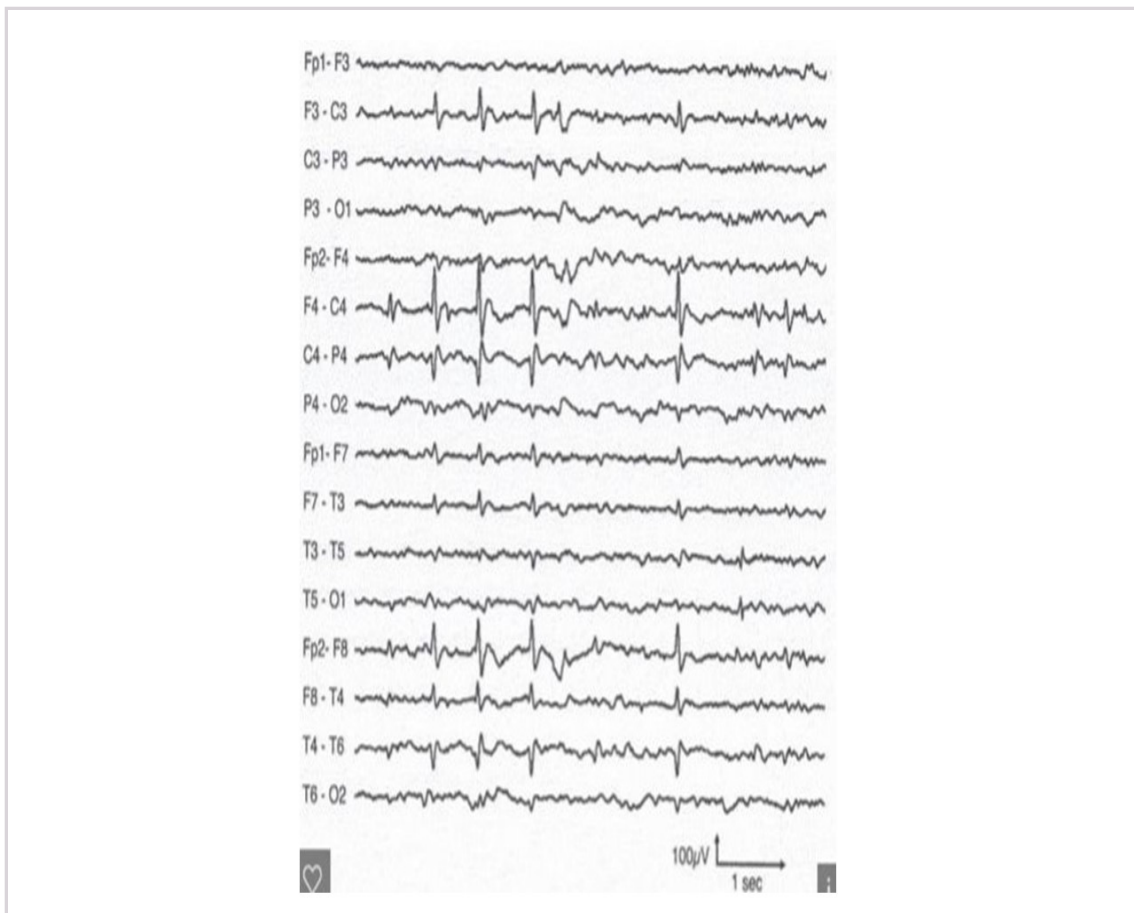- A** Prenatal
 - B** Postnatal
 - C** Unknown
 - D** Perinatal
-

000015a2a2e5f1436b

39

Hanna is 8 years old and previously healthy. She comes to the hospital in an ambulance. Her parents found her in bed, unable to make contact and with generalised clonic seizures which lasted two minutes after they found her. She is a little drowsy when she is admitted, but she has no fever, no neck stiffness and no focal neurological findings. Her mother tells you that Hanna came to her parents early in the morning a few weeks ago and could not speak for a short while (< 1 minute) but was completely conscious.

The EEG a couple of days later shows: Centrotemporal spikes (Rolandic spikes). Which epileptic syndrome is the most probable diagnosis?



- A Childhood absence epilepsy
- B Landau-Kleffner syndrome
- C Benign epilepsy of childhood (BECTS)
- D Juvenile myoclonic epilepsy

000015a2a2e5f1436ab

40

Maren was born 24 hours ago and the nurse takes a blood sample for the newborn screening. Which of the following conditions are included in the newborn screening?

- A Hypoglycaemia
- B Hypocortisolism
- C Hypopituitarism
- D Hypothyroidism

000015a2a2e5f1436ab

41

Espen is 7 years old and was admitted to hospital yesterday with debut of diabetes mellitus. He had diabetic ketoacidosis on admittance, but you have no other test results yet. What type of diabetes does Espen most probably have?

- A Type 2 diabetes mellitus
- B Monogenetic diabetes
- C MODY (maturity onset diabetes of the young)
- D Type 1 diabetes mellitus

000015a2a2e5f1436ab

42

Mathilde is 2 years and 3 months old and visits her general practitioner (GP). She is in kindergarten, and both her parents and the staff are concerned about her development during the autumn and winter. They think she often is inattentive, lacks interest in what is happening around her and seems to be in "her own world". Language development has been slow, but motor development is normal for her age. She often has a cold and needs to be kept at home. In these periods, she eats less and loses weight quickly.

Six months later, Mathilde returns to her GP. She now has normal development, no issues with making contact and her speech and language development is normal.

What steps were taken by her GP six months ago?

- A Assessment for immunodeficiency and treatment with immunoglobins
- B Training program for children with autism
- C Assessment by a special educator and follow-up by a speech therapist
- D Hearing tests and insertion of grommets (ventilation tubes)

000015a2a2e51436ab

43

As a paediatrician, you were asked to come to the orthopaedic ward to assess a 6 week old boy with second degree burns on both feet. His feet were symmetrically affected up to the ankles with a clear border between healthy and damaged skin. The parents explain that the boy was washed under running water some hours ago, but did not think the water was very warm.

What should you do?

- A Referr to dermatologist for assessment of general skin condition that makes him prone to such skin damage
- B Further investigations regarding child abuse including skeletal X-ray, cerebral CT and ophthalmoscopy. In addition, contact child welfare services and the police.
- C Further investigations regarding child abuse including skeletal X-ray, cerebral CT and ophthalmoscopy
- D Ask the ward to contact the children's health center for information about the situation at home and the parents.

000015a2a2e51436ab

44

Which agents are the most common causes of lower respiratory tract infections in Norwegian children?

- A *Streptococcus pyogenes*, *Respiratory syncytial virus (RSV)*, *Mycoplasma pneumoniae*
- B *Streptococcus pneumoniae*, *Respiratory syncytial virus (RSV)*, *Mycoplasma pneumoniae*
- C *Staphylococcus aureus*, *influenza virus*, *Mycoplasma pneumoniae*
- D *Streptococcus pneumoniae*, *Respiratory syncytial virus (RSV)*, *Chlamydia pneumoniae*

000015a2a2e51436ab

45

You are summoned to the maternity ward to examine a child born at term. She was born six hours ago, has a respiratory rate of about 75/min and has moderate chest retractions. Oxygen saturation levels are normal.

What information is the most important to retrieve?

- A Risk of infection
- B Congenital heart disease in the family
- C Arterial blood gas: pH, pCO₂, BE
- D Blood glucose level

000015a2a2e51436ab

46

Acute lymphoblastic leukemia is rare in children. When it does occur, why is it important to diagnose the leukemia as soon as possible?

- A To find out whether the disease has spread to the central nervous system
- B To find a potential bone marrow donor
- C To find out whether the disease has spread to the lymphatic system
- D To prevent serious complications and start treatment with chemotherapy

000015a2a2e51436ab

47

The parents of an 18 month old girl are concerned because they do not feel she is developing as children her same age. She sits by herself, but cannot come up into the sitting position by herself. She cannot crawl. When held in the upright position, she supports herself on her toes with crossed legs. She picks small things up with a stiff pincer grip. She makes a lot of different sounds and says "mummy" to her mother. Her tendon reflexes are lively, and there is clonus on testing the achilles reflex. With fast movement in the ankle joint, resistance can be felt. What is the most probable diagnosis?

- A Intellectual developmental disorder
- B Autism
- C Cerebral palsy (CP)
- D Neuromuscular disease

000015a2a2e51436db

48

Karl (8 years old) has always wet the bed at night. He also has a tendency to wet himself during the daytime. His mother is very concerned and takes him to the local doctor. At clinical examination, the doctor finds normal conditions apart from suspected constipation. What is the most correct way to handle this situation by the doctor?

- A Recommend that he drinks little in the evening, and start alarm mat treatment administered by the public health nurse.
- B Motivate the boy to take a laxative for a period of time and to go to the toilet regularly every day.
- C Referral of the boy to ultrasonography of the urinary tract and to the Paediatric Dept. for further investigations and treatment.
- D Reassure the parents by saying that this will disappear with time and that they can await the situation.

000015a2a2e51436db

49

As a junior doctor at a hospital, you receive a young man referred because of a palpatory hard and enlarged testical, suspect of testicular cancer. An ultrasound describes a tumour. Where would you first expect metastases and where would you first clinically examine the patient in order to detect this?

- A I would first examine the groins where you find the first lymph nodes that drain from the testicles. If lymph nodes are palpated to be normal, metastases is unlikely.
- B I would first palpate the abdomen for masses.
- C I would first palpate the left supraclavicular lymph node (Virchow's gland). If it is palpated to be normal, metastases is unlikely.
- D I would examine whether the patient has gynecomastia, since the lymph nodes surrounding the breasts are often enlarges in metastatic disease.

000015a2a2e51436db

50

You are a general practitioner and your patient has been diagnosed with multiple sclerosis (MS), and suffers from urine incontinence. Examinations at a urologic outpatient clinic has shown uninhibited contractions in the detrusor muscle (detrusor instability). She takes an anticholinergic agent, but still has urine leakage. She also suffers from a dry mouth, constipation and fatigue. You consider referring her for botox injections. What information would you give your patient about the treatment?

- A Botulinum toxin injections (Botox) results in a permanent paralysis of the bladder muscle with the need of urinary catheterisation.
- B Botulinum toxin injections (Botox) are contraindicated in neurogenic bladder dysfunction.
- C The botulinum toxin is a potent neurotoxin that paralyses the bladder muscle from 3 to 12 months.
- D Botulinum toxin injections (Botox) into the detrusor muscle will result in reduced storage capacity of the bladder.

000015a2a2e51436db

51

The patient is a 67-year-old man who uses warfarin (Marevan, anticoagulation therapy) and has previously had a kidney stone. He contacts you as his general practitioner because he has had several episodes of blood in his urine during the past weeks. He has no pain. You refer him for a "stone-CT", a one-phase CT of the urinary tract without radiocontrast. The CT shows no signs of a stone. How do you best handle this patient?

- A** You refer the patient to a three-phase CT of the urinary tract and cystoscopy at a urologic outpatient clinic.
 - B** You do a urine dipstick test twice, and if both are normal there is no need for further investigations.
 - C** Blood tests reveal that the patient is slightly overdosed on Marevan. You adjust his dose and control the blood tests in a couple of days.
 - D** A small kidney stone has most probably passed spontaneously and no further investigations are needed.
-

000015a2e2e51436ab

52

Your patient is an essentially healthy 62 year-old man who had an episode of visible blood in his urine 14 days ago. He had no pain.

Which of the following options is most correct for this patient?

- A** You check the patient with a urine test strip. If the test strip is negative for blood, no further check-ups are necessary. If the test strip is positive for blood, and if he previously has experienced kidney stones, he ought to be referred for a kidney stone CT scan without contrast.
 - B** You ought to check the patient with urine test strips 1-2 times before he is referred for cystoscopy. If both of these tests with the strips are negative for blood, he does not need any further examination.
 - C** You refer Your patient to a three-phase CT scan of the urinary tract, and to urologic outpatient clinic for cystoscopy of urethra and bladder.
 - D** Because of earlier kidney-stone anamnesis your patient has an increased cancer-risk, in this case a 4% probability of cancer.
-

000015a2e2e51436ab

53

The patient is a 35-year-old woman, pregnant for the first time and in her second trimester. She contacts the local urgent care centre where you work, because she has intense pains located in her right flank and is restless, unable to lie flat. She has normal vital signs, urine dipstick shows 2+ for blood and leukocytes, her CRP is normal. What do you do?

- A** Order a CT of the urinary tract. This is the gold standard for investigating kidney stones. A foetus in the second and third trimester can withstand radiation better than a foetus in the first trimester.
 - B** You refer the patient to a gynaecologist for examination first. If everything is normal, she should be referred to an ultrasound of the urinary tract.
 - C** Send the patient home with painkillers. Hydronephrosis and muscular pain is common in pregnancy.
 - D** You refer the patient to a urologic ward for admittance because her restlessness makes kidney stones a probable diagnosis.
-

000015a2e2e51436ab

54

A 58-year-old man contacts you as his general practitioner. For a couple of days, he has had vomiting and intense pains in his left flank that radiate to the left iliac fossa and groin. On examination, he has reduced general condition, costovertebral angle tenderness (pain on percussion of the area overlying the kidney) on the left side and has tenderness on palpating the left fossa.

Temperature: 39 degrees celcius, BT: 100/70, pulse: 110, CRP:150 (norm: < 5).

He has only had small amount of urine today, and the urine dipstick is positive for blood. He has recently had diverticulitis, and a kidney stone many years ago.

How do you proceed?

- A** This is diverticulitis. He should be sent home with antibiotics, and instructed to contact the urgent care centre if his condition deteriorates during the evening.
- B** This could be pyelonephritis. He should be sent home with antibiotics and should contact the urgent care centre if his condition deteriorates.
- C** He should be referred to the hospital for admittance on suspected early sepsis possibly from an obstructing kidney stone.
- D** Order a CT of the urinary tract within a week and send him home with antibiotics and instruct him to contact you again if his condition deteriorates.

000015a2a2e51436ab

55

When is there an absolute indication for radical therapy of bladder cancer (cystectomy or radiation therapy)?

- A** Tumor invasion of the mucosa
- B** Tumor invasion of the lamina propria
- C** Tumor invasion of muscularis propria
- D** Tumor invasion of the basal membrane

000015a2a2e51436ab

56

A 68-year old man has had increasing problems urinating over the last few years. In addition he has a history of superficial bladder cancer and is on the waiting list for transurethral bladder resection (TUR-b). He is admitted as an emergency with urine retention at 22:00. The doctor at the local emergency centre and the junior doctor at the hospital have attempted to insert a catheter without success. The patient is in great pain and there is no urine flow. Status: Temp. 38.5, pulse 90, Blood pressure 180/95. Ultrasound of the abdomen reveals 2000 ml in the bladder and bilateral hydronephrosis.

What treatment does this patient need?

- A** Intravenous antibiotics and bilateral nephrostomies
- B** Oral antibiotics and suprapubic catheter
- C** Intravenous antibiotics and immediate bilateral insertion of JJ stents
- D** Oral antibiotics and immediate cystoscopy with insertion of bladder catheter

000015a2a2e51436ab

57

Anemia is common in patients with kidney disease and GFR < 60 ml/min.

Which of the following statements is the most correct regarding the cause of anemia?

- A** Erythropoietin deficiency
- B** Erythropoietin and iron deficiency
- C** Erythropoietin and iron deficiency, as well as reduced erythrocyte life span
- D** Erythropoietin, iron and folic acid deficiency, as well as reduced erythrocyte life span

000015a2a2e51436ab

58

Generally, reaching the blood pressure target is more important than what antihypertensive agent is used. However, in some clinical situations, some antihypertensive agents are preferable over others. Which of the following statements is most correct?

- A** ACE-inhibitors should be used in congestive heart failure, chronic renal failure (eGFR < 15 ml/min/1.73m²) or diabetes mellitus.
- B** Calcium channel blockers should be used in patients with peripheral artery disease (PAD), kidney disease with proteinuria or persons from Africa.
- C** Beta blockers should be used in patients with angina pectoris, aorta aneurysms or in pregnant women.
- D** A diuretic should be used in elderly patients with isolated systolic hypertension, pregnant women or congestive heart failure.

000015a2a2e51436ab

59

A 70-year old woman is being treated for severe pneumonia and has acute kidney injury. S-creatinine has risen to 370 umol/l (normal: < 90), she has been given 3 litres of intravenous fluids (Ringer Acetat) and her blood pressure is 130/80 mmHg. Her urinary output has decreased during the last 24 hours (450 ml). ACE-inhibitors have been discontinued and the only medication she now receives is penicillin iv.

What further steps could be taken to treat her kidney injury?

- A** High dose furosemide infusion to increase tubular flow and thereby prevent precipitations here
- B** Small dose dopamine infusion to increase perfusion pressure and thereby increase GFR
- C** Start Aliskiren (medication that inhibits renin's enzyme function) to improve heart function and therefore also renal perfusion
- D** No further steps are possible

000015a2a2e51436ab

60

A patient is admitted with nephrotic syndrome. Blood pressure is 120/76 mmHg. Kidney biopsies appear normal in light microscopy, but electron microscopy reveals flattened podocytes (foot processes). The diagnosis is minimal change disease.

How should this glomerular disease be treated when diagnosed for the first time?

- A** ACE-inhibitor to reduce blood pressure
- B** Cyclophosphamide (alkylating agent)
- C** Loop-diuretics to reduce oedemas
- D** High dose corticosteroids

000015a2a2e51436ab

61

A 56-year-old woman is treated with metformin for diabetes type 2. She is overweight with BMI of 32. She uses no other medication. She comes for a routine check-up and you find: s-creatinine 99 umol/l (45-90), eGFR 55 ml/min, urine albumin/creatinine ratio 34 mg/mmol (< 3,5) and blood pressure 150/79 mmHg.

What steps could be taken to prevent further loss of kidney function?

- A** Start a statin to lower cholesterol
- B** Start an ACE-inhibitor or AT2-blocker to lower blood pressure
- C** Start an ACE-inhibitor combined with an AT2-blocker to lower blood pressure
- D** Discontinue metformin

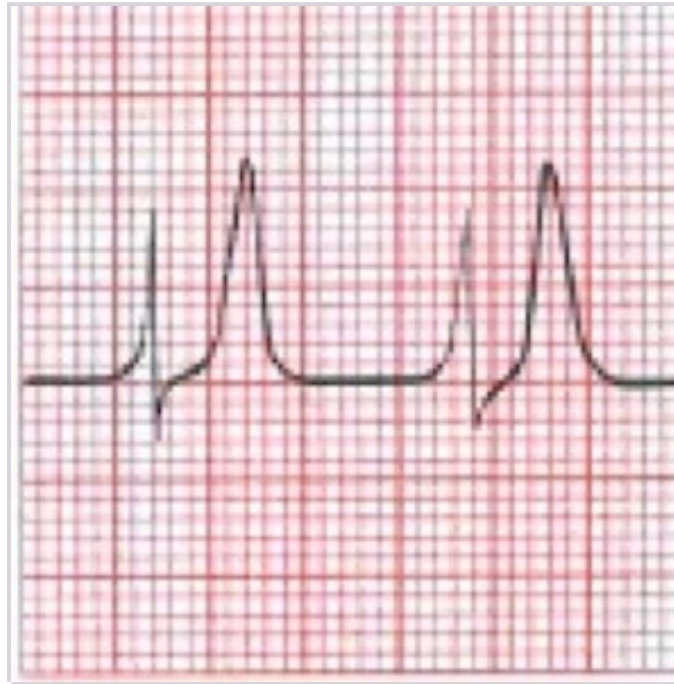000015a2a2e51436ab

62

A 55-year-old man with chronic kidney disease stage 3, is admitted to hospital due to fatigue, nausea and itchiness. He has noticed decreased urine output for the past days. He has recently had gastroenteritis with diarrhea and vomiting. He has hypertension and uses Lisinopril (ACE-inhibitor) and furosemide (loop-diuretic).

On examination you find dry mucous membranes, pulse 115/min, BP 105/66 mmHg and the ECG shows sinus tachycardia, pulse 115/min. Blood tests show: Hgb 11.0 (13,4 – 17,0) leucocytes 5,3 (4,1 – 9,8) creatinine 560 $\mu\text{mol/l}$ (60 – 105), s-K⁺ 7,6 mmol/l (3,6 – 4,6) , s- Na⁺ 134 mmol/l (137 – 145.)

How do you best manage this patient?



- A Continue ACE-inhibitor and start fluid therapy with 0,9% NaCl iv
- B Discontinue ACE-inhibitor and diuretic, and start fluid therapy with 0,9% NaCl iv
- C You contact the dialysis physician and agree to start dialysis tomorrow
- D Discontinue ACE-inhibitor and diuretic, and start fluid therapy with 0,9% NaCl iv and glucose with insulin iv

000015a2a2e51436ab

63

A 71-year-old Caucasian man with history of diabetes mellitus, coronary artery disease, hypertension, and proteinuria is treated by a primary care physician with an angiotensin-converting enzyme inhibitor (ACEI) along with other medications that are appropriate for his medical conditions. The patient is referred to you and brings an Internet printout that refers to the risks and benefits of combining the ACEI with an angiotensin receptor blocker (ARB).

Which ONE of the following is correct for describing the effects of the combination of ACEI and ARB compared with ACEI treatment alone?

- A There will be an increase in risk for allergic reactions
- B The rate of renal disease progression will be slowed
- C There is increased risk for hypotension and acute renal failure
- D The risk for cardiovascular death will be reduced

000015a2a2e51436ab

64

Anton (60) has been treated for hypertension for 4 years by his GP. Blood pressure (BP) is still 155/95 mmHg. He uses Atacand 8 mg (angiotensin receptor blocker), Selozoc 100 mg (beta-blocker) and Carduran 4 mg (alpha-blocker). Urine stix is negative. He does not smoke and has a s-cholesterol of 4.6 mmol/L (Reference: 3.9 - 7.8 mmol/L).

Which of the following statements is most correct?

- A The patient has treatment-resistant hypertension, and he should switch from Carduran to the calcium channel blocker Adalat Oros 30 mg x1
- B The patient has treatment-resistant hypertension, and must be referred to a nephrologist for further work-up and treatment
- C The patient is satisfactorily regulated as long as he does not have other risk factors for cardiovascular disease
- D The patient is satisfactorily regulated due to the absence of other risk factors, but he should increase Carduran to the full dose (8 mg) and discontinue Selozoc due to suspected side effects

000015a2a2e5f1436db

65

A 70-year-old man is treated with hemodialysis with the dialysis catheter in the v. jugularis interna. He comes to the emergency room due to a moderate fever, fatigue and dyspnoea. On examination you note a crust and moderate rubor by the dialysis catheter and blood pressure is 90/65.

What is the most probable diagnosis?

- A CMV-infection
- B Overhydration
- C Bronchitis
- D Septicaemia

000015a2a2e5f1436db

66

The patient is a 50-year-old woman who had a kidney transplant 5 years ago. She has over the past few weeks become more fatigued, has moderate heavy breathing and a light cough. She has been afebrile and has not noticed any swelling/oedema.

Blood tests show: CRP 35 (< 5), unchanged creatinine, normal leucocytes (4,1-9,8 x 10⁹/l). Arterial blood shows: pO₂ 8.2 kPa (11.0-14.4 kPa).

What is the most probable diagnosis?

- A Pneumocystis jiroveci
- B Bacterial pneumonia
- C Influenza
- D Overhydration

000015a2a2e5f1436db

67

What is the most common cause of primary adrenal insufficiency in the West?

- A Autoimmunity
- B Sarcoidosis
- C Cancer
- D Tuberculosis

000015a2a2e5f1436db

68

A 56-year-old man with type 2 diabetes has HbA_{1c} 9%. He has a normal hemoglobin, normal kidney function and there are no signs of hemolysis or abnormal hemoglobin variants.

What does his HbA_{1c} level say about his average plasma glucose level lately?

- A HbA_{1c} 9% reflects an average blood glucose of 9.0-9.4 mmol/l the last 4-6 weeks.
- B HbA_{1c} 9% reflects an average blood glucose of 11.6-12.0 mmol/l the last 4-6 weeks.
- C HbA_{1c} 9% reflects an average blood glucose of 9.0-9.4 mmol/l the last 2-3 months.
- D HbA_{1c} 9% reflects an average blood glucose of 11.6-12.0 mmol/l the last 2-3 months.

000015a2a2e5f1436db

69

A 37-year-old woman has had type 2 diabetes the past year. BMI 22 kg/m². She has had recurrent urinary tract infections, but is otherwise healthy. eGFR >90 ml/min/1.73m². She is on the maximum dose of metformin. HbA1c 8.4 %. She has never experienced hypoglycaemia. She has two children, uses birth control and has no plans of more children.

Which of the named antidiabetic drug is most suitable to add for this woman?

- A GLP-1 agonist
- B SGLT2 inhibitor
- C Long-acting insulin x 1 daily
- D Sulphonylurea

000015a2a2e51436db

70

A 42-year-old woman has had type 1 diabetes for the past 17 years. BMI 31 kg/m², eGFR > 90 ml/min/1.73m² (> 90). She has no cardiovascular disease. She is on multiple-injection therapy (long acting and rapid acting insulin analogues) and has HbA1c 8.7 %. She has recently had a severe hypoglycemic episode. She knows that SGLT2 inhibitors are not used in type 1 diabetes, but asks you as her general practitioner if you can prescribe it anyway (she will pay for it) because she knows it can give weight loss and better blood glucose control.

What is your main reason for denying her request?

- A SGLT2 inhibitors can give increased risk of diabetic ketoacidosis
- B SGLT2 inhibitors can give increased risk of cardiovascular disease
- C SGLT2 inhibitors can give increased risk of hypoglycaemia

000015a2a2e51436db

71

Woman, 65 years old, recently fractured her forearm when she slipped on the ice and fell. Her general practitioner referred her for a dual energy X-ray absorptiometry (DXA) to measure bone mineral density, which has shown osteoporosis in her lumbar spine and hip. Blood tests show moderately elevated calcium, low phosphate, normal albumin and normal 25-OH-vitamin D. There was increased urine excretion of calcium. The patient has felt well.

What is the most probable cause of hypercalcemia in this patient?

- A Familial hypocalciuric hypercalcemia
- B Sarcoidosis
- C Primary hyperparathyroidism
- D Multiple myeloma

000015a2a2e51436db

72

A 72-year-old woman with new onset atrial fibrillation comes to you as her general practitioner. She is otherwise healthy, and her mental age seems younger than her biological age. She lives alone, without any need for help.

Blood tests: Free thyroxine (FT4) 24 pmol/l (12,0 - 22,0 pmol/L) og thyroid-stimulating hormone (TSH) < 0.01 mIE/L (0,27 - 4,20 mIE/L). Negative thyroid antibodies (ie normal). Thyroid scintigraphy shows a toxic thyroid adenoma.

Which treatment would normalize thyroid status in this patient?

- A Beta blocker
- B Radioiodine therapy
- C Thyrostatic drugs (thionamides)

000015a2a2e51436db

73

A 30-year-old mother with type 1 diabetes mellitus is concerned that her daughter will also have the disease.

Approximately how large is the daughter's life time risk for the disease?

- A** 75 %
- B** 50 %
- C** 3 %
- D** 30 %

000015a2a2e5f436db

74

A 51-year-old man is concerned about having diabetes. Fasting plasma glucose is 7.1 mmol (127.8 mg/dl) and HbA1c 6.3 %. After a month, fasting plasma glucose is 7.3 mmol (131.4 mg/dl) and HbA1c 6.4 %. You are his general practitioner.

What information do you give the patient?

- A** He does not have diabetes, but has impaired glucose tolerance
- B** He has diabetes
- C** He does not have diabetes or impaired glucose tolerance

000015a2a2e5f436db

75

A 40 year old woman has felt tired and lost some weight lately, and she thinks she is more tanned than usual. On examination, she has low blood pressure and blood tests show low sodium (Na+) and elevated potassium (K+).

What is the cause of her hypotension and electrolyte disturbances?

- A** Lack of cortisol
- B** Lack of aldosterone
- C** Lack of renin
- D** Lack of ACTH

000015a2a2e5f436db

76

The patient is a 33-year-old woman from a healthy family. She comes to you as her general practitioner because she has noticed a lump on the front and somewhat downward on her neck. The lump moves on swallowing, and it is not tender. On examination there are slightly enlarged lymph nodes laterally. From talking to her, there seems to be no changes to her metabolism.

What is the best way to proceed?

- A** Thyroid status tests
- B** Ultrasound in the office by yourself
- C** Refer to a surgical ward for ultrasound
- D** Thyroid scintigraphy

000015a2a2e5f436db

77

Anne, 4-years old, has had a high fever and proven urinary tract infection that has responded well to antibiotics. The doctor plans further investigation with imaging diagnostics. She has not been investigated previously.

Which imaging investigations should the doctor refer her for first?

- A** Urography
- B** Ultrasound of the urinary tract
- C** X-ray overview of the urinary tract
- D** MRI of the urinary tract

000015a2a2e5f436db

78

Petter, 1-year old, has a fever and symptoms of an airways infection. He is debilitated and is admitted to the Paediatric Clinic. X-ray of the thorax reveals atelectasis of the right mid-lobe, small areas of atelectasis also in the other lung sections and areas with hyperinflated lung tissue bilaterally. What is the most probable diagnosis?

- A Lobar pneumonia
 - B Bronchiolitis
 - C Pulmonary sequestration
 - D Lobar emphysema
-

000015a2a2e5f1436db

79

In what situation is MRI the best imaging modality for diagnostic imaging in children?

- A Investigations for epilepsy
 - B Investigations for craniosynostosis
 - C Acute head trauma
 - D Cerebral assessment of newborns
-

000015a2a2e5f1436db

80

Which of the following conditions is the most difficult to detect with cranial ultrasound of the newborn?

- A Ischaemia
 - B Hydrocephalus
 - C Cysts
 - D Germinal matrix haemorrhage
-

000015a2a2e5f1436db

81

A 3-month-old baby is admitted to hospital with reduced general condition of unknown cause. A chest X-ray shows multiple posterior rib fractured.

Which non-radiological examination is the most important to perform?

- A Genetic testing
 - B Ophthalmoscopy
 - C Skeletal scintigraphy
 - D Spirometry
-

000015a2a2e5f1436db

82

A 59-year-old man presents with acute back pain which radiated to his left flank, before moving to his left fossa. The pain comes and goes. Urine dipstick shows 3+ for blood. You refer him for a CT scan to detect the underlying cause of the pain.

Is a CT scan with or without intravenous contrast the most appropriate, and why?

- A Without intravenous contrast because there is a high probability of detecting urinary tract stones without contrast
 - B With intravenous contrast because there is a high probability of urinary tract stone and contrast makes it easier to assess hydronephrosis
 - C Without intravenous contrast because there is a high probability that the urinary tract stone does not take up contrast
 - D With intravenous contrast because even though there is a high probability of a urinary tract stone, contrast makes excluding other differential diagnoses easier
-

000015a2a2e5f1436db

83

You have detected unilateral hydronephrosis in a foetus by ultrasound. What is the most appropriate imaging modality to start with once the child is born?

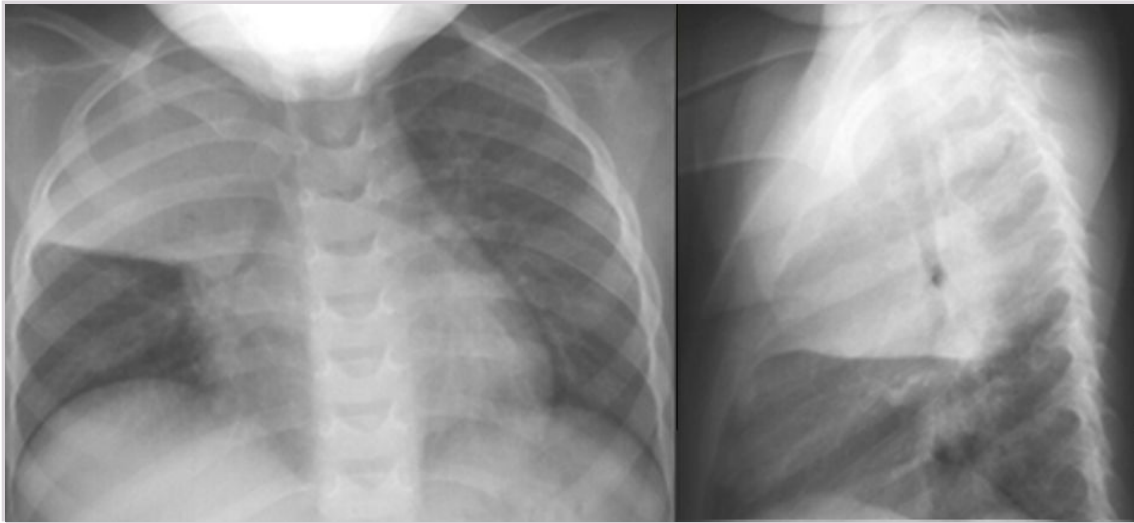
- A MRI of the urinary tract
- B Intravenous urogram
- C Ultrasound of the urinary tract
- D Micturating cystourethrogram

000015a2a2e5f1436ab

84

A 2-year-old child is admitted to hospital with a fever (39 degrees celcius) and a cough. The following X-ray is taken.

What is the most probably diagnosis?



- A Bronchiolitis
- B Empyema
- C Lobar pneumonia
- D Respiratory Distress Syndrome (RDS)

000015a2a2e5f1436ab

85

A 32-year-old man contacts his general practitioner (GP) because of swelling in one testicle that has developed during the last 6 months. It is not painful, but tender. On examination, there is clear swelling of the testicle. The GP refers him to diagnostic imaging. How urgent is diagnostic imaging in this patient?

- A Immediate admittance to hospital
- B Within 3 weeks
- C Within 3 days
- D Within 3 months

000015a2a2e5f1436ab

86

Developmental deviations are denoted differently depending on the cause.

What is a cascade of pathological findings that are caused by one primary focal defect called?

- A Association
- B Malformation
- C Syndrome
- D Sequence

000015a2a2e5f1436ab

87

Congenital tumours are rare but can have serious complications if not detected early.

What is the most common congenital tumour?

- A Sacrococcygeal teratoma
- B Nephroblastoma
- C Neuroblastoma
- D Rhabdomyosarcoma

000015a2a2e51436ab

88

Granulosa cell tumours in the ovaries of women are semi-malignant tumours that can recur after a long time.

In which subgroup of ovarian tumours are such tumours classified?

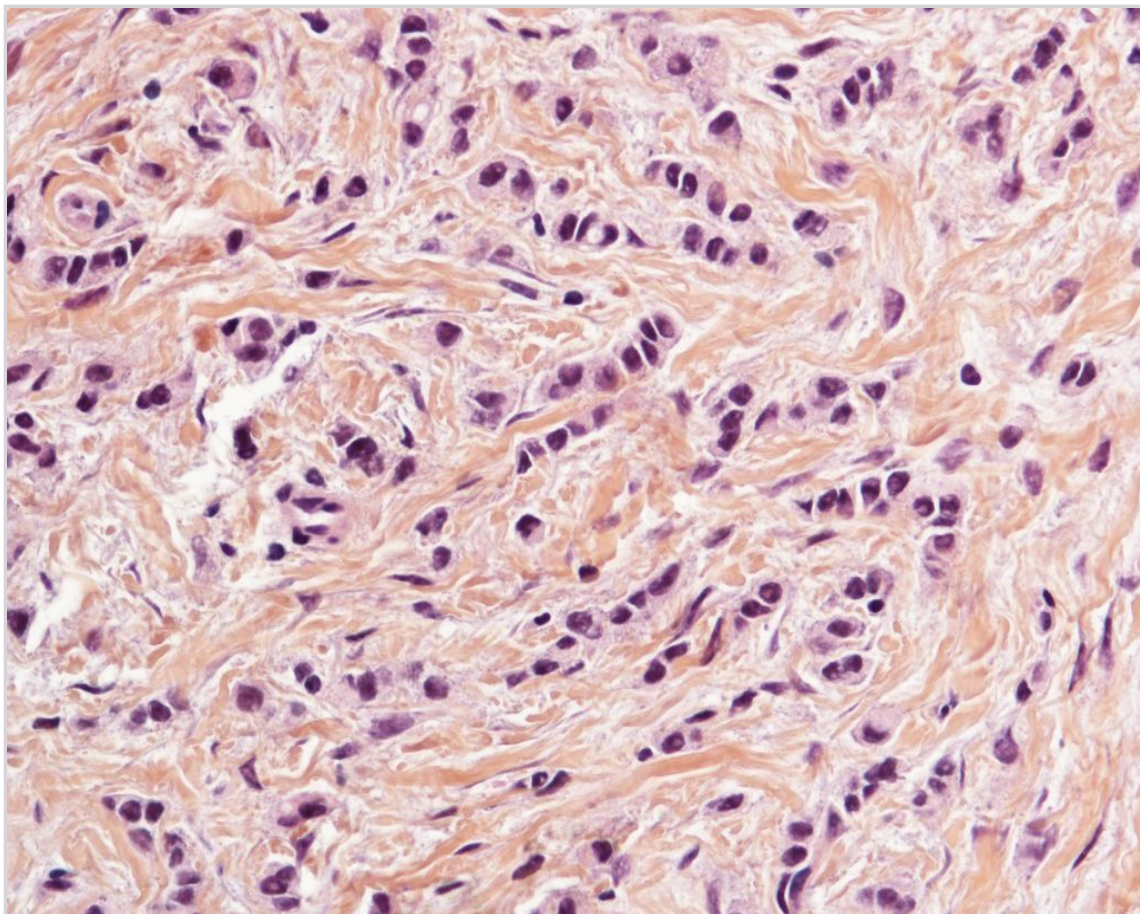
- A Germinal cell tumours
- B Sex-cord stromal tumours
- C Sarcomas
- D Epithelial tumours

000015a2a2e51436ab

89

A 60-year-old woman has noticed a change in her left breast. She undergoes surgery, and below is a histology slide from the removed tissue (HES, magnified 400x).

What is the diagnosis?



- A Fibroadenoma
 - B Lobular carcinoma
 - C Lobular carcinoma in situ
 - D Ductal carcinoma in situ
-

000015a2a2e5f1436ab

90

Both prognostic and predictive markers are used in breast cancer diagnostics.

What does a prognostic marker tell us?

- A A prognostic marker can say something about life expectancy in the absence of treatment
 - B A prognostic marker can say something about prognosis after targeted treatment
 - C A prognostic marker tells us that targeted therapy is available
 - D A prognostic marker identifies patients in whom radiation therapy is effective
-

000015a2a2e5f1436ab

91

A 10-year-old boy had a cold about two weeks ago, and has since felt tired and gained 3 kilos. He is swollen around the eyes and ankles. Urine dipstick shows 3+ for protein. Blood tests reveal hypoalbuminaemia. He is referred to the paediatric ward, and a kidney biopsy is done. There are no major changes on light microscopy, but electron microscopy shows flattened foot processes which have merged together. Apart from this, there are normal findings.

What is the most likely diagnosis?

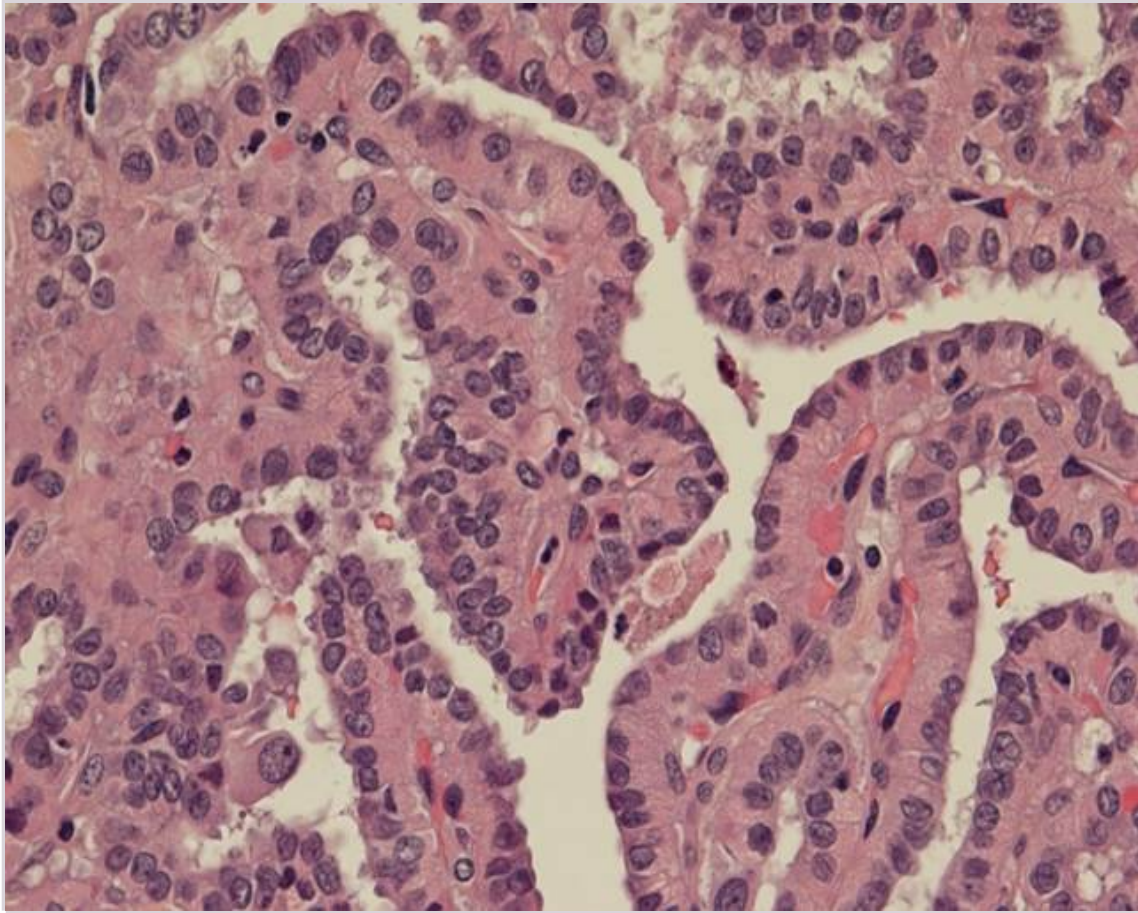
- A Membranous glomerulonephritis
 - B IgA nephropathy
 - C Minimal change disease
 - D Focal segmental glomerulosclerosis (FSGS)
-

000015a2a2e5f1436ab

92

A 24-year old man has a 5 cm tumour in the thyroid gland. It is removed surgically. The image shows a histopathologic section from the tumour (HES, X400). Genotyping of the tumour tissue reveals that he has a BRAF gene mutation.

What is the diagnosis?



- A Lymphocytic thyroiditis
- B Anaplastic carcinoma
- C Hyperplasia (Graves' disease)
- D Papillary carcinoma

000015a2a2e51436db

93

To assess the risk of complications in a pregnant woman with twins, it is important to know the type of twin placenta and fetal membranes.

In which type of twin placenta is the risk of twin-to-twin transfusion syndrome (TTTS) largest?

- A Dichorionic diamniotic placenta
- B Dichorionic monoamniotic placenta
- C Monochorionic diamniotic placenta
- D Monochorionic monoamniotic placenta

000015a2a2e51436db

94

A 28-year-old previously healthy woman comes to you as her general practitioner because of symptoms of an acute cystitis. The symptoms started two days ago, and she has never experienced similar symptoms. The history raises no suspicion of sexually transmitted disease.

What is the best way to proceed?

- A Perform a urine culture, wait for bacteria to be identified before starting antibiotic therapy
- B Perform a urine culture and start empiric antibiotic therapy
- C Give empiric antibiotic therapy for uncomplicated cystitis without urine culture

000015a2a2e51436db

95

Apron and gloves are personal protective equipment to be used in defined situations. Correct use is essential for infection control and prevention.

Which statement on infection control and prevention is the most correct?

- A Aprons and gloves belong to one room (usually the patient room) and should not be used outside that room
- B Aprons and gloves do not need to be changed regularly due to costs
- C Aprons and gloves should always be used together
- D Aprons and gloves can be used for multiple patients as long as they are in the same room

000015a2a2e5f1436ab

96

A 43-year-old man recently attended a conference where he and several other people contracted diarrhea and vomiting only 3-4 hours after eating a warm lunch.

Which microorganism is the most likely cause?

- A Salmonella enteritidis
- B Staphylococcus aureus
- C Enterotoxigenic E. coli
- D Campylobacter jejuni
- E Norovirus

000015a2a2e5f1436ab

97

A 77-year-old man with benign prostate hyperplasia and urine retention is admitted to hospital with the following clinical signs: Fever (39,5 degrees celcius), BP 80/50, pulse 125, respiratory rate 37. The physician suspects the patient has an infection.

Which antibiotic treatment should be started?

- A Ampicillin+gentamicin i.v.
- B Mecillinam i.v.
- C Ciprofloxacin i.v.
- D Cloxacillin+gentamicin i.v.

000015a2a2e5f1436ab

98

Sepsis is a serious condition where an infection can develop a systemic, self-sustaining, malignant inflammatory response. This inflammation is characterised by pro- and antiinflammatory components. What is the current definition of sepsis, which was determined in a consensus meeting in 1991?

- A Sepsis is defined by low blood pressure and high heart rate as a result of bacteria in the blood
- B Sepsis is defined as a condition where bacteria are detected in the blood
- C Sepsis is defined by elevated inflammatory markers in serum
- D Sepsis is defined as clinical and haematological variables that indicate a systemic response to infection

000015a2a2e5f1436ab

99

A 25-year-old Norwegian man has been on holiday in Thailand and had unprotected sex. Two months after coming home, his skin turns yellow and he is admitted to hospital for suspected hepatitis. On arrival, he is almost in a comatose state. Blood tests show hepatitis B virus infection (HBsAg positive) and elevated liver tests (ASAT, ALAT and bilirubin). In addition, INR is significantly elevated with values above 3.0.

How do you explain his condition?

- A The patient has a chronic hepatitis B infection and needs a liver biopsy to determine the extent of liver injury and need for further treatment
- B The patient has a chronic hepatitis B infection and needs antiviral treatment with pegylated interferon- α
- C The patient has a fulminant hepatitis B and should be discussed with a transplant unit for a transfer
- D The patient has fulminant hepatitis B and needs antiviral treatment with pegylated interferon- α

000015a2a2e5f1436ab

100

There is an epidemic with *Mycoplasma pneumoniae* and you have a patient with symptoms consistent with an atypical pneumonia. You have performed a nasopharyngeal culture/PCR, but you wish to start antibiotic treatment pending the answer.

Which antibiotic treatment should be chosen?

- A Ciprofloxacin
 - B Vancomycin
 - C Penicillin
 - D Erythromycin
-

000015a2a2e5f1436ab

101

Women who are being treated with antiepileptic drugs should use effective birth control because of possible teratogenic effects. However, this is complicated by interactions between many antiepileptic drugs and oral contraceptives.

Which mechanism is commonly responsible for a clinically relevant interaction between these two groups of drugs?

- A Antiepileptic drugs can reduce the metabolism of oral contraceptives by enzyme inhibition
 - B Antiepileptic drugs can increase the metabolism of oral contraceptives by enzyme induction
 - C Oral contraceptives can increase the free fraction of antiepileptic drugs
 - D Oral contraceptives can reduce the metabolism of antiepileptic drugs
-

000015a2a2e5f1436ab

102

Combining ACE-inhibitors and nonsteroidal anti-inflammatory drugs (NSAIDs) increases the risk of acute kidney injury.

What is the mechanism for this interaction?

- A Reduced glomerular filtration pressure due to dilation of afferent arteriole and constriction of efferent arteriole
 - B Reduced glomerular filtration pressure due to constriction of both afferent and efferent arterioles
 - C Reduced glomerular filtration pressure due to dilation of the efferent arteriole and constriction of the afferent arteriole
 - D Reduced glomerular filtration pressure due to dilation of both afferent and efferent arterioles
-

000015a2a2e5f1436ab

103

Morphine can be a problematic drug in patients with impaired kidney function. The problem is primarily retention of an active and water soluble metabolite, which results in a more pronounced and prolonged morphine effect.

What is the name of this water soluble and pharmacologically active metabolite?

- A Morphine-3-glucuronide
 - B Morphine-6-glucuronide
 - C 6-Monoacetylmorphine
 - D 3,6-Diacetylmorphine
-

000015a2a2e5f1436ab

104

The opioid-sparing effect of paracetamol is controversial, yet it is common for patients with chronic pain to take paracetamol in addition to opioids.

Some patients with chronic pain also have impaired kidney function.

Which consequences will this have for the dosing of paracetamol?

- A Paracetamol is in itself nephrotoxic and should not be used in patients with impaired kidney function
- B Paracetamol has active metabolites that are critically dependent on renal excretion, and paracetamol should therefore not be used in patients with impaired kidney function
- C Paracetamol is eliminated almost exclusively by metabolism in the liver and there is no need for a dose reduction unless the kidney function impairment is very severe
- D Paracetamol is partially metabolised in the liver and partially excreted unmetabolised, and the dose should therefore be reduced, often to half the standard dose in moderately impaired kidney function

000015a2a2e5f1436ab

105

ACE-inhibitors and angiotensin II receptor antagonists have similar side effect profiles.

What is *not* a common side effect to these two drug groups?

- A Hypokalaemia
- B Increased serum-creatinine
- C Dry cough
- D Hypotension

000015a2a2e5f1436ab

106

Thyrostatic drugs are an important part of the treatment of hyperthyroidism.

What is a common denomination of the most important drug group?

- A Thioridazines
- B Tirasethamides
- C Tiothepiates
- D Thioamides

000015a2a2e5f1436ab

107

When using angiotensin receptor blockers, it is important to monitor the patient with blood tests.

Which two blood tests are particularly important to measure?

- A Sodium and potassium
- B Creatinine and potassium
- C Uric acid and creatinine
- D Uric acid and potassium

000015a2a2e5f1436ab